

RESENTING CLINICAL SIGNS

DATE History: Recheck degenerative valve disease. Receiving pimobendan 1.875 mg BID. Pre-anesthetic evaluation (patellar surgery).

5/12/22

ECHOCARDIOGRAPHIC FINDINGS

2D, M-mode, and Doppler study.

PERFORMED BY:

Kelly Vazquez

There is moderate left atrial dilation. The mitral valve leaflets are thickened and exhibit systolic prolapse. A moderate jet of mitral regurgitation is present. There is mild left ventricular dilation. Left ventricular systolic function is hyperdynamic. The aorta and aortic valve are normal. Right atrial and right ventricular dimensions are normal. The tricuspid valve appears normal, though trace tricuspid regurgitation is present. The pulmonary artery and pulmonic valve appear normal, though trace pulmonic insufficiency is present. No pericardial effusion or cardiac masses are seen.

INTERPRETED BY

Keith Blass, DVM,
MS, DACVIM
(Cardiology)

LA - 33.1 mm
LVIDd - 28.0 mm
LVIDs - 15.3 mm
FS - 45%
RA - 18.6 mm
LVOT - 1.38 m/s
RVOT - 1.20 m/s

PATIENT

Zippy Dabney

SPECIES ASSESSMENT/RECOMMENDATIONS

Degenerative mitral valve disease

Canine

This examination demonstrates no progression of Zippy's mitral valve disease over the past 10 months. As such, his risk for the development of clinical signs secondary to it has not increased, though, given the continued presence of moderate left atrial dilation, careful monitoring of Zippy's respiratory rate/effort is still recommended.

BREED

Chihuahua Mix

Zippy's cardiovascular risk for general anesthesia, especially his risk for fluid overload, is mildly to moderately, approaching moderately, increased based on this exam, therefore, precautions should be taken in order to minimize this risk. I recommend avoiding the use of alpha-2 agonists, ketamine, and telazol in the anesthetic protocol, as well as reducing the IV fluid rate by 50%. If possible, monitoring of heart rhythm, blood pressure, and pulse oximetry are recommended during the procedure.

SEX

MN

AGE

9 y

No change in therapy is recommended based on this exam.

A recheck (X-ray +/- echocardiogram) is recommended in 6-9 months, sooner if new clinical signs compatible with cardiac dysfunction develop.

WEIGHT

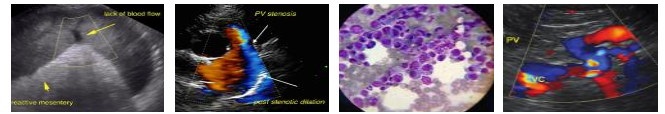
13.2 lb

HOSPITAL NAME

Westwood Regional
VH

REFERRING VET

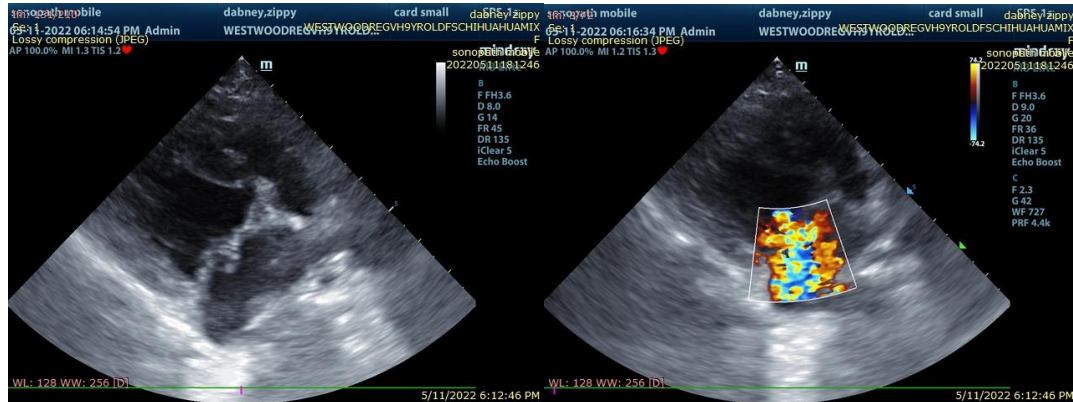
Dr. Hartwick



DATE
5/12/22

PERFORMED BY:
Kelly Vazquez

INTERPRETED BY
Keith Blass, DVM,
MS, DACVIM
(Cardiology)



PATIENT
Zippy Dabney

The information and recommendations provided are based on the images presented by the referring veterinarian. No evaluation can be communicated regarding pathology that was not visible in the image/video clips provided.

SPECIES

Thank you for this referral. If the clinical or image interpretation does not parallel your findings or if I can be of any further assistance please contact me.

Canine

Keith Blass, DVM, MS, DACVIM (Cardiology)
KeithBlass@gmail.com
631-804-5754

BREED

Chihuahua Mix

SEX

MN

AGE

9 y

WEIGHT

13.2 lb

HOSPITAL NAME

Westwood Regional
VH

REFERRING VET

Dr. Hartwick